



REVIEW ARTICLE

Tooth surface loss: A review of literature



Abdulhadi Warreth^{a,*}, Eyas Abuhijleh^b, Mohammad Adel Almaghribi^c,
Ghanim Mahwal^c, Ali Ashawish^d

^a Restorative Department, College of Dentistry, University of Science and Technology of Fujairah, United Arab Emirates

^b Orthodontic Department, College of Dentistry, University of Science and Technology of Fujairah, United Arab Emirates

^c Restorative Department, Ajman University, United Arab Emirates

^d Alzawia University, Libya

Received 22 June 2019; revised 8 September 2019; accepted 16 September 2019

Available online 24 September 2019

KEYWORDS

Tooth surface loss;
Tooth wear;
Non-carious cervical lesions;
Carbonated drink;
Gastro-oesophageal
regurgitation

Abstract Objectives: Tooth surface loss (TSL) or tooth wear (TW) is an irreversible loss of hard tooth structure caused by factors other than those responsible for dental caries. TSL is observed clinically as attrition, abrasion, abfraction, and erosion. It may be associated with symptoms such as tooth hypersensitivity and function impairment, and may lead to change in the morphology of the affected tooth. However, it may also be asymptomatic, meaning the patient may not be aware of it. In this instance, the dentist is encouraged to make the patient aware of this issue.

The aim of this review is to provide an overview of the classification and management of TSL.

Material and methods: The PubMed (MEDLINE) search engine was used to gather the most recent information on TSL. The search was restricted to a five year period (1 September 2014–31 August 2019), and only English-language studies were included. A Boolean search of the PubMed dataset was implemented to combine a range of keywords: (Tooth surface loss OR tooth wear) AND (tooth attrition OR tooth Abrasion OR tooth erosion OR tooth abfraction OR non-carious cervical lesions) AND (humans). Studies were also obtained by manual searches and from Google Scholar.

Results: By this process, 560 articles and studies were obtained. More studies were also obtained by manual searches and from Google Scholar. The most relevant published studies were chosen and used in the current review. The selected articles are included in the reference list.

* Corresponding author.

E-mail addresses: a.warreth@ustf.ac.ae, a.warreth@ajman.ac.ae (A. Warreth).

Peer review under responsibility of King Saud University.



Conclusion: TSL is a clinical problem that dentists face on a daily basis. Therefore, a sound clinical approach by which TSL can be prevented and managed is essential. While this approach requires that dentists are knowledgeable about the issue, increasing public awareness of TSL is also vital.

© 2019 Production and hosting by Elsevier B.V. on behalf of King Saud University. This is an open access article under the CC BY-NC-ND license (<http://creativecommons.org/licenses/by-nc-nd/4.0/>).

Contents

1. Introduction	54
2. Materials and methods	54
3. Classification of TSL	54
3.1. Attrition	55
3.2. Abrasion	55
3.3. Abfraction	55
3.4. Erosion	56
3.4.1. Role of saliva:	57
3.4.2. Regulation of oral pH	58
4. Management of TSL	58
5. Conclusion	58
Declaration of Competing Interest	58
References	58

1. Introduction

Tooth surface loss (TSL), or tooth wear (TW), is an irreversible loss of dental hard tissue, due to non-carious causes, which usually interact to produce destruction (Bassiouny, 2012). TSL may be considered physiological or pathological. Physiological TSL occurs as a result of mastication and adjustment, which is required for the teeth to function correctly (Kaidonis, 2008). Physiological TSL may also occur at interproximal tooth surfaces due to friction between the adjacent teeth (Davies et al., 2002, Kaidonis, 2008). Inversely, pathological TSL represents unacceptable levels of dental hard tissue loss (Bartlett et al., 2011). It is characterized by abnormal destruction, which may require treatment (Van't Spijker et al., 2009; Bartlett et al., 2011). Pathological TSL is considered to be a common clinical finding in both children and adults, and its prevalence increases with age (Smith et al. 1997; Ganss and Lussi, 2006; Van't Spijker et al., 2009). This prevalence was found to increase from 3% at the age of 20 years to 17% at the age of 70 years (Van't Spijker et al., 2009). Pathological TSL is expected to increase as the population ages and their teeth are retained for longer (Nascimento et al., 2016).

Pathological TSL lesions may be found to affect any tooth surface. However, even though each type of TSL has its own clinical appearance when present on its own, the four types may occur concurrently and interact to create a mixed TSL lesion, which may make diagnosis difficult (Harpenau et al., 2011; O'Sullivan et al., 2013; Shellis and Addy, 2014).

TSL may be asymptomatic with patients who are thus unaware of it, and it is only revealed during a clinical examination. However, it may also be symptomatic, and symptoms such as tooth hypersensitivity, function impairment and negative

effects on the patient's appearance may encourage the patient to seek dental advice.

The aim of this review is to provide an overview of the classification and management of pathological TSL.

2. Materials and methods

The PubMed (MEDLINE) search engine was used to gather the most recent information on TSL. The search was restricted to a five year period (1 September 2014–31 August 2019), and only English-language studies were included. A Boolean search of the PubMed dataset was implemented to combine a range of keywords: (Tooth surface loss OR tooth wear) AND (tooth attrition OR tooth Abrasion OR tooth erosion OR tooth abfraction OR non-carious cervical lesions) AND (humans). Articles were also obtained by manual searches and from Google Scholar without time restriction.

Using this process, 560 articles and studies were obtained. More studies were also obtained by manual searches and from Google scholar. The most relevant published studies were chosen and used in the current review. The selected articles are included in the reference list.

3. Classification of TSL

There is a general agreement that TSL is a multifactorial condition that has a complex aetiology (Lussi, 2006, Lussi et al., 2011), with one or more factors contributing greatly. Therefore, the causes and nature of TSL should be considered when making a diagnosis and formulating a treatment plan. Collectively TSL can be described as a combination of attrition, abrasion, abfraction or erosion (bio-corrosion).

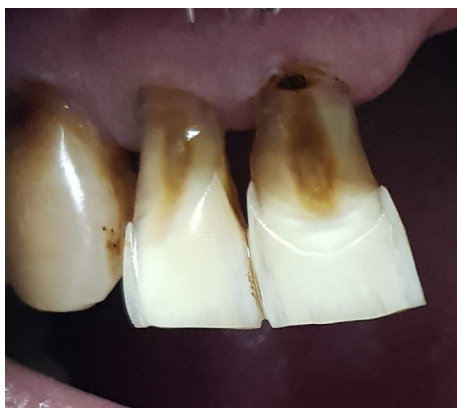

Fig. 1 Cervical abrasion lesions caused by the aggressive use of the chewing stick (Miswak).

These represent the clinical picture of the effect and give an indication of the aetiology.

3.1. Attrition

Attrition is defined as the wear process of the tooth tissue by direct tooth-to-tooth contact (Davies et al., 2002; Chu et al., 2002; Addy and Shellis, 2006; O'Sullivan et al., 2013). It is usually seen as well-defined wear facets on the surfaces of teeth in one jaw which match corresponding facets on opposing teeth in the other jaw. Attrition can be seen on cusps and guiding surfaces during empty-mouth grinding movements as in para-functional habits (i.e., bruxism). When the cause of attrition is active, the tooth wear is usually seen as shiny and well-defined facets (Kaidonis, 2008).

Several factors are reported to predispose the occurrence of attrition. These factors include coarse porcelain on opposing natural teeth and occlusal collapse due to a lack of posterior support (Chu et al., 2002).

3.2. Abrasion

Abrasion is a type of TSL that is caused by the sliding or rubbing of abrasive external objects against the tooth surfaces (Addy and Shellis, 2006). Several factors are reported to cause such TSL. These factors include the use of an abrasive toothpaste, hard bristles, and a vigorous brushing technique (Litonjua et al., 2005). It may also be caused by the use of toothpicks and miswaks, as well as the consumption of abrasive foods (Fig. 1). Abrasion lesions can also be seen on the occlusal surfaces as wear areas rather than facets, which are characteristic of attrition. This is because occlusal abrasion involves the whole occlusal table (Kaidonis, 2008). When compared with those caused by erosion, abrasion lesions are associated with relatively shallow cupping and exposed dentine that is not usually hypersensitive. The lack of hypersensitivity is attributed to the formation of a mechanical smear layer that blocks the exposed dentinal tubules (Kaidonis, 2008). Furthermore, an acid attack on the teeth compromises their mechanical properties and makes them more susceptible to the other causes of TSL, as in the case of abrasion (He et al., 2011). Clinically, cervical abrasions are commonly seen as V-shaped notches in the cervical regions of facial surfaces of one or more

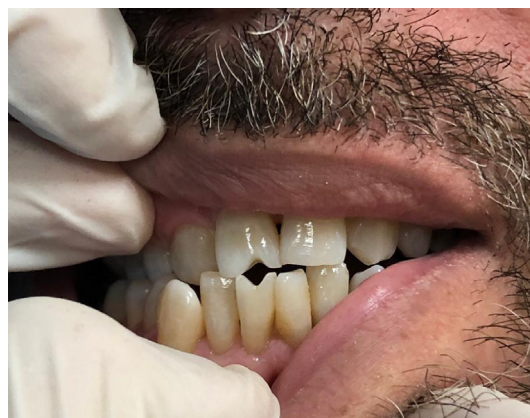

Fig. 2 Abrasion lesions are caused by the consumption of dried sunflower seeds and are a result of keeping the shell vertically and applying force in order to crack it.

teeth. They are characterized by sharply defined margins and smooth surfaces. Despite the general belief that cervical abrasions are caused by toothbrushes, toothpaste and brushing techniques, a definite conclusion is difficult to draw, as other factors such as erosion and abfraction may also play a role in the development of abrasion lesions (Davies et al., 2002; Litonjua et al., 2005).

Abrasive TSL may also be seen on the occlusal surfaces as a result of diet, the chewing of abrasive materials like tobacco or continuous exposure to dust and grit (Turner and Missirlian, 1984). It can also be caused by the consumption of vegetables that have not been properly washed and, therefore, still contained trace amounts of soil (Levrini et al., 2014). Other factors such as pipe-smoking, thread biting and holding hair-pins between the teeth can cause an abrasion in the involved tooth surface (Chu et al., 2002; Rath et al., 2017). Abrasion lesions developed as a result of the consumption of dry sunflower seeds are shown in Fig. 2.

3.3. Abfraction

Abfraction is a type of TSL believed to be caused by tensile stress generated from non-axial cyclic occlusal forces (Grippio, 1991; Chu et al., 2002). According to *The Glossary of Prosthodontic Terms* (2017), "abfraction is defined as the pathologic loss of hard tooth substance caused by biomechanical loading forces; such loss is thought to be the result of flexure and chemical fatigue degradation of enamel and/or dentin at some location distant from the actual point of loading." It has been reported that abfraction lesions are affected by factors such as the location, magnitude, duration and frequency of the forces.

The theory of abfraction suggests that tooth flexure in the cervical area is caused by compressive occlusal forces and tensile stresses, resulting in microfractures of the hydroxyapatite crystals of the enamel and dentin with further fatigue and deformation of the tooth structure (Chu et al., 2002; Lee et al., 2002; Rees, 2006). However, despite many efforts to demonstrate that occlusal forces are the main cause of abfraction, its etiology remains poorly understood and controversial (Michael et al., 2009).

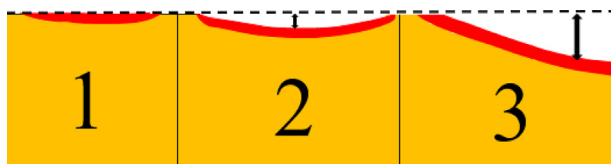


Fig. 3 Different stages in the continuous erosion process (Modified from Lussi et al., 2011): 1. Softening of the enamel red area with no material loss, 2. Partial material loss (Black arrow) and softening of the underlying surface (subsurface) (Red area), 3. Significant loss of material (Black arrow) and softening of the underlying surface (Red area).

Clinical presentations of cervical abfraction lesions are observed primarily on the facial surfaces. They are typically wedge- or V-shaped lesions with clearly defined internal and external angles (Rees et al., 2003) that resemble the abrasion lesions, which makes it difficult to differentiate between the two lesion types. However, abfraction lesions can also manifest themselves as C-shaped defects with rounded floors or of mixed-shape with flat cervical and semi-circular occlusal walls (Hur et al., 2011). Furthermore, abfraction lesions can also be seen on occlusal surfaces where they are present as circular invaginations (Davies et al., 2002). Cervical abfraction may also be seen extending subgingivally (Davies et al., 2002), thereby distinguishing it from abrasion. However, they may be any one of these shapes, although they may also be present simultaneously and overlap.

3.4. Erosion

Traditionally, dental erosion is defined as the dissolution of dental hard tissue caused by non-bacteriogenic acids (Meurman and ten Cate, 1996; Addy and Shellis, 2006). It has been reported that 29% of European adults aged 18–35 years old showed signs of erosion (bio-corrosion), making it a common clinical finding in this group.

The severity of the damage caused by erosion depends on several factors such as the type, concentration, and temperature of the acid involved and its time of contact with the tooth surfaces (West et al., 2000). Other factors such as pH, titratable acidity, ion concentrations, and frequency and method of exposure also affect the erosive potential (Barbour and Rees, 2006).

The distribution and severity of TSL lesions that are initiated by erosion depend on how the acidic materials came into contact with the tooth surface. For example, erosion caused by gastro-oesophageal regurgitation disorder (GERD) occurs on the palatal aspect of the upper anterior teeth and usually does not affect the lower posterior teeth as the tongue protects them. When erosion is caused by prolonged holding and swishing acidic drinks, the labial aspects of tooth surface are more likely to be affected first (Johansson et al., 2004).

Erosion usually starts with the softening of the tooth surface by acidic materials (Fig. 3). When tooth enamel is exposed to acid, it loses minerals from its superficial layer, which extends to a depth of a few microns. The thickness of this softened layer ranges from 0.02 to 3 μm (Lussi et al., 2011). When the acid attacks and the softening process continues, dissolution of the most superficial layer occurs, and it is entirely lost (Barbour and Rees, 2006). It is important to mention that

erosion affects not only the tooth surface, but its destructive effects extend below the surface (subsurface). Hence, it involves removal and softening of the tooth surface material along with dissolution of minerals beneath the surface. Part of the affected subsurface may remain attached to the affected tooth as shown in Fig. 3 (Lussi, 2006; Lussi et al., 2011; Shellis et al., 2013).

The softened enamel is physically fragile and unstable, even against mild physical impact, which is attributed to its high degree of demineralization (Eisenburger, 2009). In its early stages, erosion affects the enamel layer, resulting in a shallow, smooth, glazed surface that usually lacks developmental ridges and stain lines and is usually free from plaque deposits (Hattab and Yassin, 2000; Mehtha et al., 2012).

Erosion can be a result of two interrelated types of wear: formation of the softened layer, which is fragile and susceptible to mechanical wear, and entire dissolution of enamel. Additionally, the outer surface of the softened layer may also be too friable to resist friction; hence, it may be lost (Eisenburger et al., 2004). However, remineralization of this softened layer is possible and this can occur as a result of incorporating calcium and phosphate into it to rebuild the

Table 1 Etiological factors of the erosive type of TSL (Modified from O'Sullivan et al., 2013; Carvalho et al, 2016).

Drinks (Beverages): [Low pH and a high buffer capacity (resisting changes in pH)]
o Highly acidic, low pH carbonated soft drinks (contain two main acids: citric and phosphoric acid)
o Energy drinks
o Fruit juices
o Alcohol based drinks such as dry wine, cider and alcopops
o Fruit flavored alcoholic drinks
Food: [Low pH and a high buffer capacity]
o Fresh fruits (citrus, grapes and sour apples)
o Pickled food
o Vinegars
o Vinaigrette
o Sauce such as ketchup and brown sauce
o Crisps
o Flavored chewing gum (sugar-containing and acid-base)
Medications and other products
o Such as aspirin and vitamin C when they are used as chewable tablets or effervescent drinks
o Acidic oral hygiene products/mouthwashes
o Those which induce dry mouth and affect buffering capacity of saliva
o Acidic salivary stimulants
o Those which induce nausea and vomiting
Lifestyle
o Frequent consumption of sport drinks such as Lucozade over an extended period of time
o Swallowing of swimming pool water with poorly buffered chlorine (leads to formation of hydrochloric acid)
o Sugar-sweetened beverages
o Mood enhancing drugs such as Ecstasy
Occupation
o Work related exposure to erosive materials such as wine tasting or sulfuric acid mist in a battery factory
Internal sources
o Regurgitation,
o Vomiting and
o Ruminations

hydroxyapatite mineral layer. Calcium and phosphate ions can be obtained from saliva and/or from other sources.

The critical pH at which enamel becomes susceptible to erosion is estimated to be 5.5. Hence, when an acidic material whose pH is at or below this level comes into contact with enamel frequently and for a prolonged period of time, enamel erosion occurs (Meurman and ten Cate, 1996). In prismatic enamel, acid attacks lead to its demineralization. This is due to the dissolution of either the prism cores or the inter-prismatic areas. The eroded prismatic enamel may also have a microscopic honeycomb appearance. This is because the prismatic enamel is dissolved by acid, while the inter-prismatic enamel remains extended above the surface (Levrini et al., 2014). In aprismatic enamel, the dissolution pattern is more irregular, with various degrees of mineral loss (Meurman and ten Cate, 1996).

Dentine is more susceptible to erosion than enamel, and it can be eroded at a relatively high pH (~6.0) (Vanuspong et al., 2002, Zebrauskas et al., 2014). There are two reasons for this high susceptibility: the carbonate content of dentine is greater than that of enamel (6% versus 3%), and the crystals in dentine are much smaller than those of enamel. The latter structure makes more surface area of dentine available for an acid attack (Featherstone and Lussi, 2006).

Erosion can be caused by both intrinsic and/or extrinsic acids (Table 1) and modified by changes in salivary flow and constituents. Intrinsic acid is gastric acid, which crosses from the stomach into the oesophagus and reaches the mouth. It is a result of regurgitation (gastric reflux), vomiting, or rumination (O'Sullivan et al., 2013). The pH of gastric juice is very low (~1) (Meurman and ten Cate, 1996). It contains hydrochloric acid and low concentrations of calcium and phosphate (Dawes, 2003).

It has been reported that 64% of patients with palatal erosion had gastro-oesophageal regurgitation disorder (GERD) (Bartlett et al., 1996), which represents a retrograde flow of gastric juice and/or duodenal contents into the distal oesophagus. However, it has also been reported that 30% of patients who had palatal erosions had no symptoms of GERD (Bartlett et al., 1996). Nevertheless, these patients are considered to be silent refluxers. Further, GERD should be considered as a cause of erosion in patients with indigestion, heartburn, or epigastric pain. Furthermore, chronic coughing, asthma-like symptoms and laryngitis may also be associated with GERD. Factors such as alcoholism-induced gastritis and hiatus hernia may also cause acid regurgitation and lead to erosion. Furthermore, conditions such as pregnancy and obesity may cause an increase in gastric pressure, therefore causing acid reflux and erosion (Levrini et al., 2014).

Erosion is also associated with recurrent vomiting (i.e., spontaneous or self-induced). While spontaneous vomiting may be a sign of an underlying medical condition, self-induced vomiting is common among patients with eating disorders such as bulimia.

Conversely, extrinsic acids are found in foods such as wine, carbonated or fizzy drinks, citrus fruit and juice. Extrinsic acids are also found in certain medications, workplaces (e.g., vaporized sulphuric acids from batteries), energy drinks, and swimming pools with poorly buffered chlorine sterilisation (Zebrauskas, 2014). Reduced salivary flow following surgical excision of one or more major salivary glands, Sjögren's syndrome, drug intake (e.g., antidepressants, sedatives, tranquiliz-

Table 2 Signs of TSL caused by acid (erosion) [Carvalho et al 2016].

- Erosion lesions usually have rounded edges
- Flattening of the occlusal structures, cupping of the cusps
- In severe cases occlusal anatomy may completely disappear
- The lingual and labial smooth surfaces are flattened and an intact enamel rim along the gingival margin may be present (Fig. 3)
- Concavities of the affected tooth surface may occur
- A decrease in the occlusal vertical dimension (OVD) and an increase in the inter-occlusal space
- A proud restoration such as an amalgam restoration
- Lesions may affect enamel only or may also extend into dentine
- Lesions may be localized thereby affecting a single tooth and/or surface
- Lesions may be generalized, symmetrically or asymmetrically distributed

ers), or radiotherapy in the head and neck region also predisposes a patient to dental erosion (Table 1).

Alcohol in itself is erosive, though less so than acids; but consumption may induce gastric acid reflux. Therefore, erosion that is associated with alcohol consumption may be caused by a combination of extrinsic (alcohol) and intrinsic acid sources (gastric acid) (O'Sullivan et al., 2013). Furthermore, some mouthwashes have a pH below 5.5, which may also cause tooth erosion (Claffey, 2003).

When erosion develops slowly, as when caused by eating and drinking, it is usually asymptomatic, and the patient is unlikely to seek treatment. Hence, it may progress without any noticeable symptoms. On the other hand, erosion may progress faster in certain patients, such as those with eating disorders. This then leads to dentine hypersensitivity; additionally, the aesthetic is negatively affected. Therefore, patients are more likely to seek treatment. The signs of TSL that are caused by acid (erosion) are displayed in Table 2.

There are two essential features of erosion that may be useful in distinguishing erosion lesions from abrasion ones. Firstly, when erosion is active, this is usually accompanied by dentine hypersensitivity, whereas abrasion lesions are not usually associated with hypersensitivity. Secondly, cupping is usually deeper with erosion than with abrasion (Kaidonis, 2008). This may aid in determining the cause of TSL and consequently, in diagnosis.

3.4.1. Role of saliva:

Saliva has a key role to play in the protection of hard tissue against decay and the erosive type of TSL. TSL is reportedly associated with buffering capacity, variation in calcium ion concentration and salivary flow rate (Carvalho et al., 2016). The tooth demineralisation caused by bacterial acids or acids in food can be inhibited by the saliva bicarbonate content that increases the pH and buffering capacity of saliva. Factors such as flow rate, electrolyte and protein composition and buffer capacity of saliva affect the speed by which saliva returns to its saturated state and regains its remineralisation potential after acid threat. These factors also affect the inter-individual variations in combating dental erosion.

3.4.2. Regulation of oral pH

The buffering capacity of human saliva is regulated by three systems.

1. The carbonic acid/bicarbonate system
2. The phosphate system
3. The proteins

The bicarbonate concentration is strongly dependent on the salivary flow. Furthermore, the enzyme bacterial urease can convert salivary urea to ammonia, a base which neutralizes acid. Saliva can reduce the demineralization rate by providing calcium, phosphate and fluoride ions to restore eroded enamel and dentine (Hara and Zero, 2014). Saliva also has the ability to dilute and wash away the causative acid (Carvalho et al., 2016).

It also neutralizes and buffers acids, thereby minimizing their contact with teeth. Further, the salivary pellicle adheres to the tooth surface immediately after brushing and forms a physical barrier, which protects the underlining tooth surface against a direct acid attack (Hannig and Balz 2001; Hannig et al., 2004, Featherstone and Lussi 2006; Honório et al., 2010). Thus, it reduces the amount of mineral dissolution after a short event of acid exposure. Therefore, saliva has a negative effect on the occurrence and severity of TSL and protects the tooth surface from attack.

4. Management of TSL

Management of TSL varies according to the cause, complexity and severity of the condition. Depending on the underlying cause of TSL, the patient may be referred for further investigation, and liaising with physicians may also be required (O'Sullivan et al., 2013). When TSL is minimal, monitoring and the use of simple direct restorations are the principal treatment options. However, when it is severe, restorative treatment with interdisciplinary long-term management may be needed.

A detailed social, medical and dental history of the patient, as well as an accurate clinical examination supported with other measures, such as salivary flow rate and radiographs, are required to enable the clinician to reach an accurate diagnosis and make an effective treatment plan. In some patients, long-term monitoring is required before commencing any irreversible invasive treatment (Smith et al., 1997). It should be noted whether the observed lesion(s) is/are active, the rate of progress, whether the lesion(s) is/are symptomatic and if the patient is concerned about the aesthetic of teeth. These are of paramount importance and should be addressed before commencing treatment. Furthermore, liaising with physicians may be essential to identify and develop management programs for any causative medical conditions (O'Sullivan et al., 2013).

Several methods are used in diagnosis and to monitor TSL. These methods include a scratch test in which a scratch is made on the tooth surface with a scalpel blade. The scratch disappearing or diminishing in time is an indication that erosion has occurred. Serial colour photographs can also be used to compare changes in enamel translucency and shade of the affected enamel. Dental casts made at different times are compared to find out whether or not erosion has occurred (Kaidonis, 2012).

One useful method by which the degree of TSL is recorded and monitored is known as a basic erosive wear examination (BEWE) (Bartlett et al., 2008). This method is based on dividing the dentition into sextants and recording the highest score of each sextant. According to the severity of the erosive lesions, a treatment, monitoring and follow-up plan are tailored to suit each patient. This method is more efficient when combined with 3D images that may be useful in early diagnosing and monitoring of TSL (Marro et al., 2018). Furthermore, intra-oral scanners may also be used to diagnose and detect advanced tooth wear (Kumar et al., 2019).

Fluoride application is considered to be a gold standard for the management of dental erosion (Schlueter et al., 2016, Carvalho and Lussi, 2014, Alexandria et al., 2017). In addition, several *in vitro* studies have reported on the beneficial effects of modified acidulated phosphate fluoride (APF) gel containing nano-hydroxyapatite (nHAp) (Soares et al., 2018; Dionysopoulos et al., 2019a), Casein-phosphopeptide-stabilised amorphous calcium phosphate nanocomplexes (CPP-ACP) (Fernando et al., 2019), bioglass (Dionysopoulos et al., 2019a), and laser treatment (Vlacic et al., 2007; Esteves-Oliveira et al., 2017). These materials and techniques seem to be promising. However, robust clinical studies are required to confirm the effectiveness of such materials as *in vitro* study results cannot be extrapolated to real clinical situations. Furthermore, complete protection against the development of erosion by the application of these materials may not always be achievable (Dionysopoulos et al., 2019b).

5. Conclusion

TSL is a clinical problem that dentists face on a daily basis. Therefore, a sound clinical approach with which TSL can be prevented and managed is essential. Whereas this approach requires that dentists are knowledgeable about the issue, increasing public awareness of TSL is also vital.

Declaration of Competing Interest

The authors declared that there is no conflict of interest.

References

- Addy, M., Shellis, R.P., 2006. Interaction between attrition, abrasion and erosion in tooth wear. *Monogr. Oral Sci.* 20, 17–31.
- Alexandria, A.K., Vieira, T.I., Pithon, M.M., da Silva Fidalgo, T.K., Fonseca-Gonçalves, A., et al, 2017. *In vitro* enamel erosion and abrasion-inhibiting effect of different fluoride varnishes. *Arch. Oral Biol.* 77, 39–43.
- Barbour, M.E., Rees, G.D., 2006. The role of erosion, abrasion and attrition in tooth wear. *J Clin Dent.* 17, 88–93.
- Bartlett, D.W., Evans, D.F., Anggiansah, A., Smith, B.G., 1996. A study of the association between gastro-oesophageal reflux and palatal dental erosion. *Br. Dent. J.* 181, 125–131.
- Bartlett, D., Ganss, C., Lussi, A., 2008. Basic Erosive Wear Examination (BEWE): a new system for scientific and clinical needs. *Clin. Oral. Investig.* 12 (Suppl 1), S65–S68.
- Bartlett, D.W., Fares, J., Shirodaria, S., Chiu, K., Ahmad, N., Sherriff, M., 2011. The association of tooth wear, diet and dietary habits in adult aged 18–30 years old. *J. Dent.* 39, 811–816.
- Bassiouny, M.A., 2012. Effect of sweetening agents in acidic beverages on associated erosion lesions. *Gen Dent.* 60, 322–330.

- Carvalho, T.S., Lussi, A., 2014. Combined effect of a fluoride-, stannous- and chitosan-containing toothpaste and stannous-containing rinse on the prevention of initial enamel erosion-abrasion. *J. Dent.* 42, 450–459.
- Carvalho, T.S., Colon, P., Ganss, C., Huysmans, M.C., Lussi, A., Schlueter, N., Schmalz, G., et al, 2016. Consensus report of the European federation of conservative dentistry: erosive tooth wear diagnosis and management. *Swiss Dent J.* 126, 342–346.
- Chu, F.C., Yip, H.K., Newsome, P.R., Chow, T.W., Smales, R.J., 2002. Restorative management of the worn dentition: 1. Aetiol. Diagnosis. *Dent. Update* 29, 162–168.
- Claffey, N., 2003. Essential oil mouthwashes: a key component in oral health management. *J. Clin. Periodontol.* 30 (Suppl 5), 22–24.
- Davies, S.J., Gray, R.J.M., Qualtrough, A.J.E., 2002. Management of tooth surface loss. *Br. Dent. J.* 192, 11–23.
- Dawes, C., 2003. What is the critical pH and why does a tooth dissolve in acid? *J. Can. Dent. Assoc.* 69, 722–724.
- Dionysopoulos, D., Tolidis, K., Sfeikos, T., 2019a. Effect of CPP-ACPF and nano-hydroxyapatite preventive treatments on the susceptibility of enamel to erosive challenge. *Oral Health Prev Dent.* 17, 357–364.
- Dionysopoulos, D., Tolidis, K., Sfeikos, T., 2019b. Effect of air-abrasion pre-treatment with bioactive glass 45S5 on enamel surface loss after erosion/abrasion challenge. *Dent. Mater.* <https://doi.org/10.1016/j.dental.2019.05.009> [Epub ahead 2019 of print].
- Eisenburger, M., Shellis, R.P., Addy, M., 2004. Scanning electron microscopy of softened enamel. *Caries Res.* 38, 67–74.
- Eisenburger, M., 2009. Degree of mineral loss in softened human enamel after acid erosion measured by chemical analysis. *J. Dent.* 37, 491–494.
- Esteves-Oliveira, M., Wollgarten, S., Liebegall, S., Jansen, P., Bilandzic, M., Meyer-Lueckel, H., et al, 2017. A new laser-processing strategy for improving enamel erosion resistance. *J. Dent. Res.* 96, 1168–1175.
- Featherstone, J.D., Lussi, A., 2006. Understanding the chemistry of dental erosion. *Monogr. Oral Sci.* 20, 66–76.
- Fernando, J.R., Shen, P., Sim, C.P.C., Chen, Y.Y., Walker, G.D., Yuan, Y., Reynolds, C., et al, 2019. Self-assembly of dental surface nanofilaments and remineralisation by SnF₂ and CPP-ACP nanocomplexes. *Sci. Rep.* 9, 1285.
- Ganss, C., Lussi, A., 2006. Diagnosis of erosive tooth wear. *Monogr. Oral Sci.* 20, 32–43.
- Grippio, J.O., 1991. Abfraction: a new classification of hard tissue lesions of teeth. *J. Esthet. Dent.* 3, 14–19.
- Hannig, M., Balz, M., 2001. Protective properties of salivary pellicles from two different intraoral sites on enamel erosion. *Caries Res.* 35, 142–148.
- Hannig, M., Fiebiger, M., Guntzer, M., Döbert, A., Zimehl, R., Nekrashevych, Y., 2004. Protective effect of the in situ formed short-term salivary pellicle. *Arch. Oral Biol.* 49, 903–910.
- Hara, A.T., Zero, D.T., 2014. The potential of saliva in protecting against dental erosion. *Monogr. Oral Sci.* 25, 197–205.
- Harpenau, L.A., Noble, W.H., Kao, R.T., 2011. Diagnosis and management of dental wear. *J. Calif. Dent. Assoc.* 39, 225–231.
- Hattab, F., Yassin, O., 2000. Etiology and diagnosis of tooth wear: a literature review and presentation of selected cases. *Int. J. Prosthodont.* 13, 101–107.
- He, L.H., Xu, Y., Purton, D.G., 2011. In vitro demineralisation of the cervical region of human teeth. *Arch. Oral Biol.* 56, 512–519.
- Honório, H.M., Rios, D., Júnior, E.S., de Oliveira, D.S., Fior, F.A., Buzalaf, M.A., 2010. Effect of acidic challenge preceded by food consumption on enamel erosion. *Eur. J. Dent.* 4, 412–417.
- Hur, B., Kim, H.C., Park, J.K., Versluis, A., 2011. Characteristics of non-carious cervical lesions—an ex vivo study using micro computed tomography. *J. Oral Rehabil.* 38, 469–474.
- Johansson, A.K., Lingström, P., Imfeld, T., Birkhed, D., 2004. Influence of drinking method on tooth-surface pH in relation to dental erosion. *Eur. J. Oral Sci.* 112, 484–489.
- Kaidonis, J.A., 2008. Tooth wear: the view of the anthropologist. *Clin. Oral. Invest.* 12 (Suppl 1), S21–S26.
- Kaidonis, J.A., 2012. Oral diagnosis and treatment planning: part 4. Non-carious tooth surface loss and assessment of risk. *Br. Dent. J.* 213, 155–161.
- Kumar, S., Keeling, A., Osnes, C., Bartlett, D., O’Toole, S., 2019. The sensitivity of digital intraoral scanners at measuring early erosive wear. *J. Dent.* 81, 39–42.
- Lee, H.E., Lin, C.L., Wang, C.H., Cheng, C.H., Chang, C.H., 2002. Stresses at the cervical lesion of maxillary premolar—a finite element investigation. *J. Dent.* 30, 283–290.
- Leverini, L., Di Benedetto, G., Raspanti, M., 2014. Dental wear: a scanning electron microscope study. *Biomed Res. Int.* 340425. <https://doi.org/10.1155/2014/340425>.
- Litonjua, L.A., Andreana, S., Cohen, R.E., 2005. Toothbrush abrasions and noncarious cervical lesions: evolving concepts. *Compend. Contin. Educ. Dent.* 26, 767–768, 770–774, 776.
- Lussi, A., 2006. Erosive tooth wear - a multifactorial condition of growing concern and increasing knowledge. *Monogr. Oral Sci.* 20, 1–8.
- Lussi, A., Schlueter, N., Rakmatullina, E., Ganss, C., 2011. Dental erosion—an overview with emphasis on chemical and histopathological aspects. *Caries. Res.* 45 (Suppl 1), 2–12.
- Mehta, S.B., Banerji, S., Millar, B.J., Suarez-Feito, J.M., 2012. Current concept on the management of tooth wear: Part 1. Assessment, treatment planning and strategies for the prevention and the passive management of tooth wear. *Br. Dent. J.* 212, 17–27.
- Meurman, J.H., ten Cate, J.M., 1996. Pathogenesis and modifying factors of dental erosion. *Eur. J. Oral Sci.* 104, 199–206.
- Michael, J.A., Townsend, G.C., Greenwood, L.F., Kaidonis, J.A., 2009. Abfraction: separating fact from fiction. *Aust. Dent. J.* 54, 2–8.
- Marro, F., De Lat, L., Martens, L., Jacquet, W., Bottenberg, P., 2018. Monitoring the progression of erosive tooth wear (ETW) using BEWE index in casts and their 3D images: a retrospective longitudinal study. *J. Dent.* 73, 70–75.
- Nascimento, M.M., Dilbone, D.A., Pereira, P.N., Duarte, W.R., Geraldini, S., Delgado, A.J., 2016. Abfraction lesions: aetiology, diagnosis, and treatment options. *Clin. Cosmet. Investig. Dent.* 8, 79–87.
- O’Sullivan, E., Barry, S., Milosevic, A., Brock, G., 2013. Diagnosis, Prevention and Management of Dental Erosion. (The 2013 Guideline). Royal College of Surgeon publications.
- Rath, A., Ramamurthy, P.H., Fernandes, B.A., Sidhu, P., 2017. Effect of dried sunflower seeds on incisal edge abrasion: a rare case report. *J. Conserv. Dent.* 20, 134–136.
- Rees, J., 2006. The biomechanics of abfraction. *Proc. Inst. Mech. Eng. H.* 220, 69–80.
- Rees, J., Hammadeh, M., Jagger, D., 2003. Abfraction lesion formation in maxillary incisors, canines and premolars: a finite element study. *Eur. J. Oral Sci.* 111, 149–154.
- Schlueter, N., Lussi, A., Tolle, A., Ganss, C., 2016. Effects of erosion protocol design on erosion/abrasion study outcome and on active agent (NaF and SnF₂) efficacy. *Caries Res.* 50, 170–179.
- Shellis, R.P., Addy, M., 2014. The interactions between attrition, abrasion and erosion in tooth wear. *Monogr. Oral Sci.* 25, 32–45.
- Shellis, R.P., Barbour, M.E., Jesani, A., Lussi, A., 2013. Effects of buffering properties and undissociated acid concentration on dissolution of dental enamel in relation to pH and acid type. *Caries Res.* 47, 601–611.
- Smith, B.G., Bartlett, D.W., Robbo, N.D., 1997. The prevalence, aetiology and management of tooth wear in the United Kingdom. *J. Prosthet. Dent.* 78, 367–372.
- Soares, L.E.S., da Silva Magalhães, J., Marciano, F.R., Lobo, A.O., 2018. Surface characteristics of a modified acidulated phosphate fluoride gel with nano-hydroxyapatite coating applied on bovine enamel subjected to an erosive environment. *Microsc. Res. Tech.* 81, 1456–1466.

- The Glossary of Prosthodontic Terms, 2017. Ninth edition. *J. Prosthet Dent.* 117, e1–e105.
- Turner, K., Missirlian, D.M., 1984. Restoration of the extremely worn dentition. *J. Prosthet. Dent.* 52, 467–474.
- Van't Spijker, A., Rodriguez, J.M., Kreulen, C.M., Bronkhorst, E.M., Bartlett, D.W., Creugers, N.H., 2009. Prevalence of tooth wear in adults. *Int. J. Prosthodont.* 22, 35–42.
- Vanuspong, W., Eisenburger, M., Addy, M., 2002. Clinical tooth wear and sensitivity: erosion, softening and rehardening of dentine; effects of pH, time and ultrasonication. *J. Clin. Periodontol.* 29, 351–357.
- Vlacic, J., Meyers, I.A., Walsh, L.J., 2007. Laser-activated fluoride treatment of enamel as prevention against erosion. *Aust. Dent. J.* 52, 175–180.
- West, N.X., Hughes, J.A., Addy, M., 2000. Erosion of dentine and enamel in vitro by dietary acids: the effect of temperature, acid character, concentration and exposure time. *J. Oral Rehabil.* 27, 875–880.
- Zebrauskas, A., Birskute, R., Maciulskiene, V., 2014. Prevalence of dental erosion among the young regular swimmers in Kaunas, Lithuania. *J. Oral. Maxillofac. Res.* 5, e6.